


MP 20-10

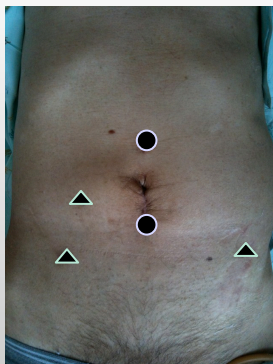


Perioperative results of laparoscopic radical cystectomy
Toru HARABAYASHI
Hokkaido Cancer Center, Sapporo, JAPAN



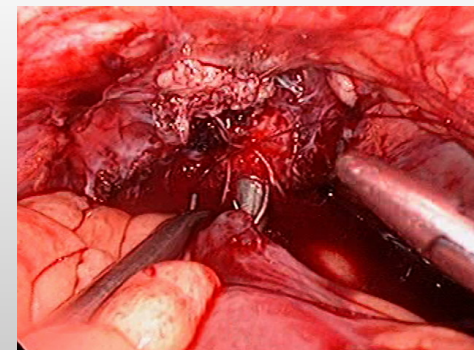
	Laparoscopy	Open
Period	Dec 2009 –Apr 2011	Jun 2008-
No.	22	17
Clinical stage $\leq T1/T2 \leq$	11 / 12	8 / 9
Past operative history	6	2
ASA score $3 \leq$	4	1
Preoperative therapy	5	4

1. 5-trocker method with camera-port 5cm above the umbilicus.



● 10mm
▲ 5mm

4. Extracorporeal neobladder construction & laparoscopic anastomosis.





	Laparoscopy	Open
Continent diversion	10 (45%)	6 (29%)
Operation time (h)	6.0 (4.2 - 8.7)	6.2 (5.2-7.3)
Bleeding (mL)	587 (131- 2440)	1363 (459-3845)
No transfusion (%)	16 (73%)	1 (6%)
Intraoperative event	2 Open conversion	1
Food diet (day)	5	6.5
Early complications (G3 _≤)	4 (18%) Fecal leakage 1	4 (24%) Wound dehiscence 1
Mortality	0	0
Positive margin	2 (9%)	1 (6%)
No. dissected nodes	19 (6-36)	14 (5-26)
Follow-up (mos)	15 (3-22)	27 (4-41)